Journal of Pediatric Surgery xxx (xxxx) xxx

Contents lists available at ScienceDirect

Journal of Pediatric Surgery

journal homepage: www.elsevier.com/locate/jpedsurg

Intraoperative intercostal nerve cryoablation during the Nuss procedure reduces length of stay and opioid requirement: A randomized clinical trial☆

Claire E. Graves, Jarrett Moyer, Michael J. Zobel, Roberto Mora, Derek Smith, Maura O'Day, Benjamin E. Padilla *

Division of Pediatric Surgery, Department of Surgery, University of California, San Francisco.

ARTICLE INFO

Article history:
Received 7 November 2018
Received in revised form 29 January 2019
Accepted 22 February 2019
Available online xxxx

Key words:
Pectus excavatum
Nuss procedure
Intercostal nerve cryoablation
Thoracoscopic

ABSTRACT

Purpose: Minimally-invasive repair of pectus excavatum by the Nuss procedure is associated with significant postoperative pain, prolonged hospital stay, and high opiate requirement. We hypothesized that intercostal nerve cryoablation during the Nuss procedure reduces hospital length of stay (LOS) compared to thoracic epidural analgesia.

Design: This randomized clinical trial evaluated 20 consecutive patients undergoing the Nuss procedure for pectus excavatum between May 2016 and March 2018. Patients were randomized evenly via closed-envelope method to receive either cryoanalgesia or thoracic epidural analgesia. Patients and physicians were blinded to study arm until immediately preoperatively.

Setting: Single institution, UCSF-Benioff Children's Hospital.

Participants: 20 consecutive patients were recruited from those scheduled for the Nuss procedure. Exclusion criteria were age < 13 years, chest wall anomaly other than pectus excavatum, previous repair or other thoracic surgery, and chronic use of pain medications.

Main outcomes and measures: Primary outcome was postoperative LOS. Secondary outcomes included total operative time, total/daily opioid requirement, inpatient/outpatient pain score, and complications. Primary outcome data were analyzed by the Mann–Whitney U-test for nonparametric continuous variables. Other continuous variables were analyzed by two-tailed t-test, while categorical data were compared via Chi-squared test, with alpha = 0.05 for significance.

Results: 20 patients were randomized to receive either cryoablation (n = 10) or thoracic epidural (n = 10). Mean operating room time was 46.5 min longer in the cryoanalgesia group (p = 0.0001). Median LOS decreased by 2 days in patients undergoing cryoablation, to 3 days from 5 days (Mann–Whitney U, p = 0.0001). Cryoablation patients required significantly less inpatient opioid analgesia with a mean decrease of 416 mg oral morphine equivalent per patient (p = 0.0001), requiring 52%–82% fewer milligrams on postoperative days 1–3 (p < 0.01 each day). There was no difference in mean pain score between the groups at any point postoperatively, up to one year, and no increased incidence of neuropathic pain in the cryoablation group. No complications were noted in the cryoablation group; among patients with epidurals, one patient experienced a symptomatic pneumothorax and another had urinary retention.

Conclusions and relevance: Intercostal nerve cryoablation during the Nuss procedure decreases hospital length of stay and opiate requirement versus thoracic epidural analgesia, while offering equivalent pain control.

Type of study: Treatment study.

Level of evidence: Level I.

© 2019 Elsevier Inc. All rights reserved.

Pectus excavatum, characterized by a depression of the anterior chest wall, is the most common congenital chest wall deformity, with a prevalence of approximately 6.3 to 12 per 1000 worldwide [1]. First introduced in the 1990s, the Nuss procedure, also known as the minimally-invasive repair of pectus excavatum (MIRPE), is now the most common procedure for operative correction [2–5]. Though benefits of this approach include smaller incisions, shorter operative time, and less blood loss when compared to the open Ravitch repair [3], the instantaneous reshaping of the chest wall is associated with significant postoperative pain. [6–9] Currently, the two most common pain control strategies following the Nuss procedure are thoracic epidural infusion and intravenous patient-controlled analgesia (PCA). [7,10–12] In

☆ Trial Registration: ClinicalTrials.gov; ID: NCT02721017.https://clinicaltrials.gov/ct2/show/NCT02721017

* Corresponding author at: University of California, San Francisco Department of Surgery Division of Pediatric Surgery 550 16th St, Fifth Floor San Francisco, CA 94158-0570 United States.

E-mail address: benjamin.padilla@ucsf.edu (B.E. Padilla).

https://doi.org/10.1016/j.jpedsurg.2019.02.057
0022-3468/© 2019 Elsevier Inc. All rights reserved.

addition, a variety of multimodal regimens utilizing chest wall indwelling catheter infusions and local or regional nerve blocks have recently been proposed to lessen pain and decrease perioperative opioid use [13–19]. However, these regimens all provide relatively short-term pain control, while pain from the Nuss procedure often persists for 2 to 4 weeks [20].

In order to provide long-acting pain control at the time of surgery, cryoanalgesia has been used for peripheral nerve blockade [21–23]. "Cryoanalgesia" refers to the use of cold temperature to disrupt peripheral nerve function [24]. The idea of using ice or cold temperatures to numb pain dates at least to the time of Hippocrates (460–377 BC) who described the use of ice and snow packs to relieve surgical pain [25,26]. The modern version of this ancient concept uses a commercially-available "cryoprobe" which releases high-pressure carbon dioxide or nitrous oxide, rapidly cooling to −50 to −70 °C. This causes Wallerian degeneration of the nerve axons, temporarily preventing pain transmission. The fibrous outer neural structures remain intact, which facilitate complete axonal regeneration by approximately 4–6 weeks [25,27–30]. We hypothesized that patients undergoing cryoanalgesia would have significantly decreased postoperative length of stay, and reduced in-hospital opioid requirements when compared to patients receiving thoracic epidural for the Nuss procedure.

1. Materials and methods

1.1. Study design

This was a prospective, randomized clinical trial of patients undergoing the Nuss procedure for pectus excavatum (Fig. 1) at a single academic institution. Patients were randomized in a 1:1 ratio via closed-envelope method to receive either cryoanalgesia or thoracic epidural analgesia for perioperative pain control. Patients and physicians were blinded to study arm until the envelope was opened in the preoperative waiting area. All procedures were reviewed and approved by the institutional review board.

1.2. Patient selection and enrollment

Patients were recruited consecutively from those who had already been scheduled to undergo the Nuss procedure. Only otherwise healthy patients with pectus excavatum deformity were included. The study was open to adults and children of any gender, race, and ethnicity. Patients with any of the following were excluded from participation: 1) age < 13 years at time of procedure; 2) chronic use of pain medication preoperatively; 3) pectus carinatum, Poland's syndrome, or any chest wall anomaly other than pectus excavatum; 4) previous repair of pectus excavatum by any technique; 5) previous thoracic surgery; 6) congenital heart disease; 7) bleeding dyscrasia; 8) major anesthetic risk factors or history of previous problem with anesthesia; 9) pregnancy; 10) non-English speaker. Informed consent was obtained at time of enrollment from the patient, or in the case of minors, informed assent was obtained from the patient, as well as consent from both parents.

1.3. Randomization

Before enrollment, the numbers 1 to 20 were randomly assigned to cryoanalgesia or thoracic epidural groups in a 1:1 ratio using a computerized random sequence generator (http://www.random.org). The assignments were placed in closed envelopes by a third party, uninvolved with the study, with the integers on the outside of the envelopes. As patients were enrolled in the study, they were consecutively assigned their patient number in order of enrollment. The envelope associated with each patient number was opened in the preoperative area just prior to time of surgery, revealing the patient's group assignment.

1.4. Nuss procedure and analgesia

All patients underwent the Nuss procedure, performed by a single attending pediatric surgeon with extensive experience performing the procedure. Specifics of the procedure (i.e., one vs. two bar implants, location of fixation, number of stabilizers) were left to the discretion of the operating surgeon based on individual patient factors. However, the same general repair protocol was followed for all patients: small incisions were made on each side of the chest wall, and a subcutaneous tunnel was created for Nuss bar insertion just medial to the pectus ridge. Separate incisions were made more laterally for insertion of the thoracoscope. Under thoracoscopic guidance, the retrosternal space was developed and a Lorenz passer was advanced across the mediastinum. The passer was exchanged for a Nuss bar, which was bent to a custom configuration for each patient. The bar was introduced with convexity facing posteriorly, then flipped inside the patient, so that the convexity was anterior, which forced the sternum anteriorly and corrected the pectus excavatum. The bar was secured to the ribs with bilateral stabilizers.

Patients randomized to cryoanalgesia were intubated with a double-lumen endotracheal tube for better lung isolation and exposure of the posterolateral course of the intercostal nerves. Patients were treated with the AtriCure cryosurgical system (AtriCure, Inc., West Chester, Ohio) during the Nuss procedure. All wounds were infiltrated with 0.25% Marcaine prior to incision. An additional 5 mm incision was made on each side in the midclavicular line low in the chest for the thoracoscope, and the cryoprobe was inserted through the bar insertion wound. The cryoprobe was directly applied to the intercostal nerve, posterolateral to the chest wall incisions, under thoracoscopic visualization at the level of the incision and 2 interspaces above and below, bilaterally. Cryoablation was performed by applying the cryoprobe to the intercostal nerves for 2 min to achieve a temperature of −60 °C. Each nerve received one cycle of cryoablation.

Patients randomized to epidural analgesia were intubated with a single-lumen endotracheal tube. A thoracic epidural catheter was placed by the pediatric anesthesia team immediately prior to the Nuss procedure. Catheters were placed using sterile technique at approximately T5–6 or T6–7 interspaces; procedure specifics were left to the discretion of the attending anesthesiologist. After placement, epidural infusion was begun with 0.1% ropivacaine and 2 μg/cc fentanyl. No bolus doses were administered. Patients in the cryoanalgesia arm did not receive preoperative thoracic epidural placement, and patients in the epidural arm did not receive intraoperative cryoanalgesia.

1.5. Postoperative care

Postoperative care and analgesic protocol were identical for all patients with the exception of continuous epidural infusion (no bolus or patient-controlled epidural analgesia). All patients were admitted to the pediatric inpatient unit under the pediatric surgery service. The study team, in conjunction with the pediatric pain service, developed a multimodal postoperative pain regimen (Appendix A), which was used to guide medication prescription and dosing by the pediatric surgical service for patients in both treatment groups. Local field block was performed intraoperatively at all incision sites. All patients received a hydromorphone PCA, standing intravenous acetaminophen, and 48 h of standing ketorolac immediately postoperatively. Once patients were tolerating a diet, they were converted to oral oxycodone, acetaminophen, and ibuprofen. Per institutional protocol, all epidurals were weaned at the discretion of the pediatric pain management team in consultation with the primary surgical team. Both managing teams assessed patients twice daily for readiness to wean and/or discontinue the epidural. Narcotic usage was recorded and tracked through the hospital's electronic medical record. In addition to standard postoperative nursing assessments and service rounds, patients' pain (including neuropathic-specific pain described as "burning", "electrical" or

Please cite this article as: C.E. Graves, J. Moyer, M.J. Zobel, et al., Intraoperative intercostal nerve cryoablation during the Nuss procedure reduces length of stay and opioid requ..., Journal of Pediatric Surgery, https://doi.org/10.1016/j.jpedsurg.2019.02.057

ARTICLE IN PRESS

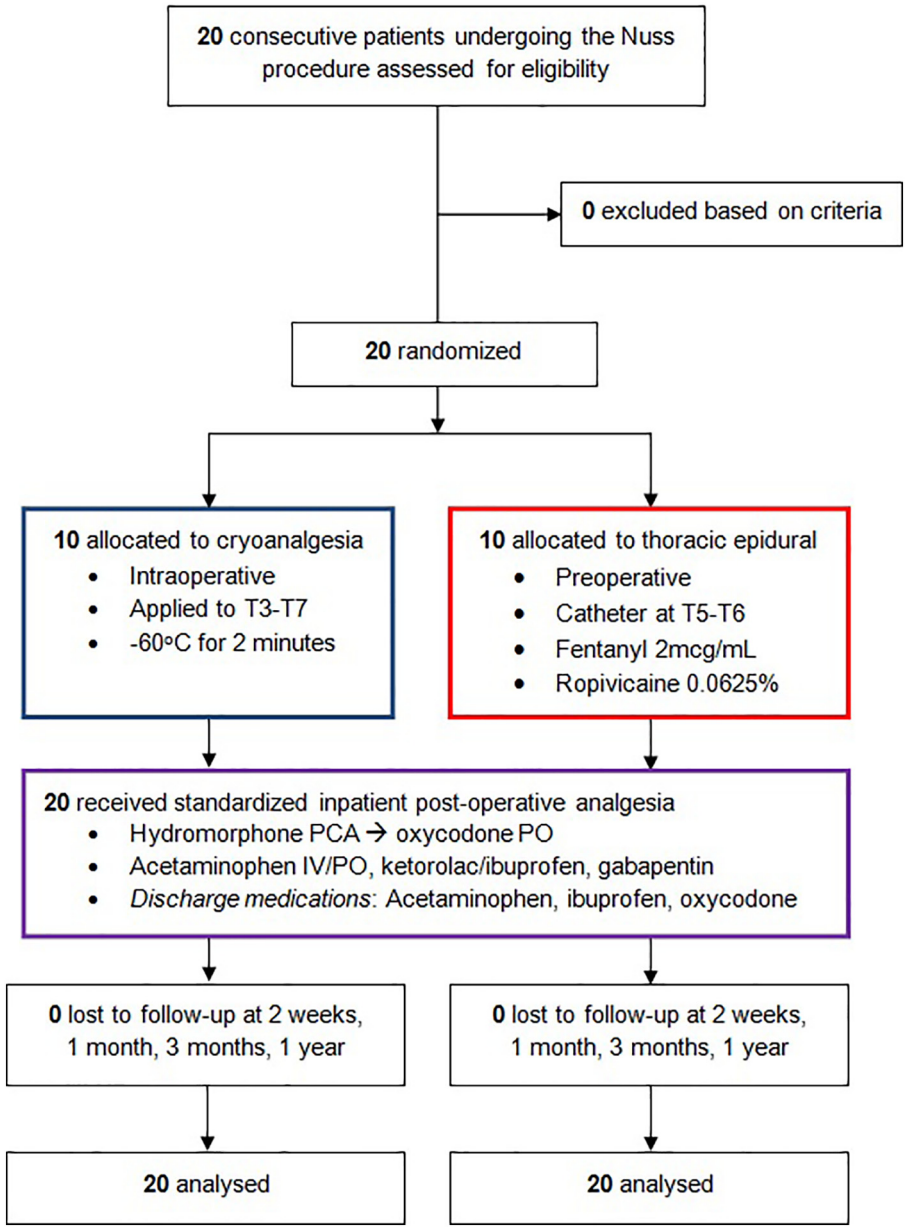

Fig. 1. CONSORT diagram of enrollment and follow-up.

"tingling" sensations) was assessed by study questionnaire via numerical pain scale (1 to 10, with 10 representing a maximum score) twice per day in sitting and lying position. Discharge was determined by the pediatric surgery attending based on adequate pain control with oral medications, ability to walk independently, and diet tolerance.

1.6. Follow-up

Upon discharge, patients were sent home with acetaminophen, ibuprofen and oxycodone and were instructed to keep a medication log. Patients were scheduled for follow-up appointments at 2 weeks, 1 month, 3 months, and 1 year from the date of their surgery. Each visit consisted of an interim history and a focused physical exam, including specific assessment of incision sites, chest wall sensation, and epidural catheter site. Each patient also completed a survey at each appointment that included questions about type and severity of pain, satisfaction with pain control regimen, level of physical activity, and side effects or adverse events.

1.7. Endpoints, power calculation, and data analysis

Primary outcome was postoperative length of stay (LOS). Secondary outcomes included total operating room and procedure time, narcotic usage (milligram oral morphine equivalent), adjunct analgesia usage, epidural- or cryoanalgesia-related side effects, pain scores, presence of neuropathic pain, presence and duration of chest numbness, and procedural complications. Postoperative LOS was chosen as an objective measure that synthesizes many different aspects of a procedure and its subsequent postoperative course (including adverse events, pain control, psychosocial issues, etc.). The study was powered to demonstrate a statistically significant effect (type 1 error rate 0.05, type II error rate 0.1), based on preliminary studies [22] demonstrating decreased LOS by 2 days in patients undergoing cryoanalgesia. To allow for up to 10% unexpected patient dropout, 20 patients were enrolled.

Primary outcome data were analyzed by comparing the median LOS with the Mann–Whitney U test for nonparametric continuous variables. All other continuous variables were analyzed by comparison of means via a two-tailed t-test, while categorical data were compared with the

Please cite this article as: C.E. Graves, J. Moyer, M.J. Zobel, et al., Intraoperative intercostal nerve cryoablation during the Nuss procedure reduces length of stay and opioid requ..., Journal of Pediatric Surgery, https://doi.org/10.1016/j.jpedsurg.2019.02.057

Chi-squared test. All data were analyzed using an intention-to-treat analysis

2. Results

Between May 23, 2016 and March 16, 2018, 20 patients meeting inclusion criteria underwent thoracoscopic Nuss procedure: 10 were randomized to receive intraoperative intercostal nerve cryoablation and 10 were randomized to receive a thoracic epidural. No eligible patients were excluded from the study. All patients received the intended intervention, and there was no crossover between the two groups. All patients receiving thoracic epidural were followed for one year. Patients undergoing cryoanalgesia received postoperative follow-up to one year with the exception of one patient who had not yet reached the one year mark, and one patient who was lost to follow-up after seven months (Median follow-up 12 months in both groups; Cryoablation follow-up range: 7–12 months). Both patients who did not reach one year of follow-up reported return of normal chest wall sensation and pain scores of 3 or lower at the 3-month follow-up exams.

Patients randomly assigned to receive cryoablation were 3.8 years older than those undergoing thoracic epidural (Mean Difference 95% C.I. 2.9–6.6 years; p-value = 0.03). There were no other significant differences in patient demographic, clinical or radiologic features (Table 1). Patients undergoing cryoablation were 176.2 cm tall, weighed 62.9 kg with a mean Haller Index of 4.2, compared to 175.8 cm, 62.9 kg and a Haller Index of 3.7 in patients receiving an epidural.

2.1. Primary outcome

Median LOS decreased by 2 days in patients undergoing cryoablation, relative to those receiving an epidural. Specifically, patients receiving cryoablation were discharged on median postoperative day (POD) 3 (range: POD 2–4), while those receiving an epidural were discharged on median POD 5 (range: POD 4–6; Mann–Whitney U p = 0.0001). As illustrated in Fig. 2, all 10 patients undergoing cryoablation were discharged home by POD 4. In the epidural analgesia group, 4 of 10 patients were discharged on POD 4, while the remaining six patients were discharged on POD 5 or POD 6.

2.2. Secondary outcomes

2.2.1. Analgesia requirements

Patients who underwent cryoablation required significantly less opioid analgesia than those undergoing epidural. For the entire postoperative stay, patients in the intercostal nerve cryoablation group required a mean 268 mg (range 150–386 mg; Std Dev 165.2 mg) total oral morphine equivalents, compared to a mean 684 mg (range 547–821 mg; Std Dev 191.8 mg) in patients receiving thoracic epidural (mean difference: 416 mg; p = 0.0001). The decreased opioid requirement was not attributable to the shorter length of postoperative stay based on comparison of daily opiate requirements. As shown in Fig. 3, patients undergoing cryoanalgesia received 52% less opioid on POD 1, 76% less on POD 2, and 82% less on POD 3 (p-value <0.01 for all three time points). Additionally, patients receiving cryoablation required less total ketorolac (mean decrease 89.3 mg, p = 0.02) and less acetaminophen (mean decrease 848.1 mg, p = 0.01).

Table 1
Demographic, clinical, and radiologic characteristics.

	Thoracic Epidural (n = 10)	Cryoablation (n = 10)	p-value[a]
Age, years			
Mean (Range)	16.1 (13–21)	20.9 (14–31)	***0.03***
Male Gender (%)	80	90	0.52
Height, mean (cm)	175.8	176.2	0.94
Weight, mean (kg)	61.2	62.9	0.90
ASA Class (%)			1.0
ASA I	5	5	
ASA II	5	5	
Haller Index			
Mean (Range)	3.7 (2.9–5.1)	4.2 (3.6–5.7)	0.12

[a] p-value calculated using 2-tailed t-test for continuous variables, and χ^2 test for categorical variables.

2.3. Postoperative pain and sensation

There was no difference in mean pain scores between the two randomization groups at any in-hospital or outpatient time points, up to one year (Table 2). Patients undergoing cryoanalgesia did not demonstrate increased levels of neuropathic-type pain, described as "burning", "electrical" or "tingling" sensations, relative to those who received a thoracic epidural. All patients undergoing cryoanalgesia demonstrated anterior chest wall numbness at initial outpatient follow-up. However, sensation returned to normal in 6 of 10 patients at three months postoperatively, and in all patients by one year postprocedure.

2.4. Operative outcomes

All patients had successful correction of pectus excavatum. As shown in Table 2, operating room and operative times were longer by 46.5 min and 68.5 min, respectively, for patients receiving cryoanalgesia (p = 0.0001). There was no difference in intra- or postoperative complication rates. There were no complications in the cryoablation group. In the epidural group, one patient required insertion of a chest pigtail drain for symptomatic pneumothorax on POD 0, and another patient had a urinary catheter inserted for postoperative urinary retention.

3. Discussion

Postoperative pain management has remained a significant challenge in corrective procedures for pectus excavatum. In this prospective randomized trial, our results demonstrate a significantly shorter length of stay and decreased postoperative opioid requirement in patients who received cryoanalgesia during the Nuss procedure when compared to thoracic epidural. This is the first randomized trial to study differences between cryoanalgesia versus epidural analgesia, and supports previous retrospective case series that also found shortened length of stay and decreased narcotic usage with cryoanalgesia [22,23,31,32]. Importantly, cryoanalgesia and epidural analgesia provide equally effective pain control despite the substantial decrease in opioid consumption associated with cryoablation, as evidenced by equivalent inpatient and long-term postoperative pain scores. With further institutional experience with cryoablation, we believe there is potential for even shorter postoperative stays following its application. In fact, while median LOS following cryoablation in our study was three postoperative days, the final three ablated patients were all discharged home on postoperative day 2. PCA was part of the post-Nuss pain control regimen in both groups as a means of readily treating and quantifying pain in the event that the epidural or cryoablation were ineffective. Eliminating the routine use of PCA may further shorten hospital stays, consistent with the 1.5-day length of stay reported by Sujka et al. [23] Our current post-Nuss pain control strategy uses cryoablation and oral pain medications, without PCA.

Current post-Nuss procedure pain control is largely based on opioid administration. Common opioid side effects include itching, sedation, nausea and constipation, in addition to more serious effects such as respiratory depression. Moreover, opioid use can induce dependence, a major issue at the root of the current national epidemic of opioid misuse and abuse. As a result, reducing opioid usage can provide not only short-term, but also long-term improvement on patient safety and quality of life. Multimodal techniques are standard of care in postoperative pain management, and improve pain scores while decreasing opioid use. While blocks (local, regional, or central regional) and catheter-based

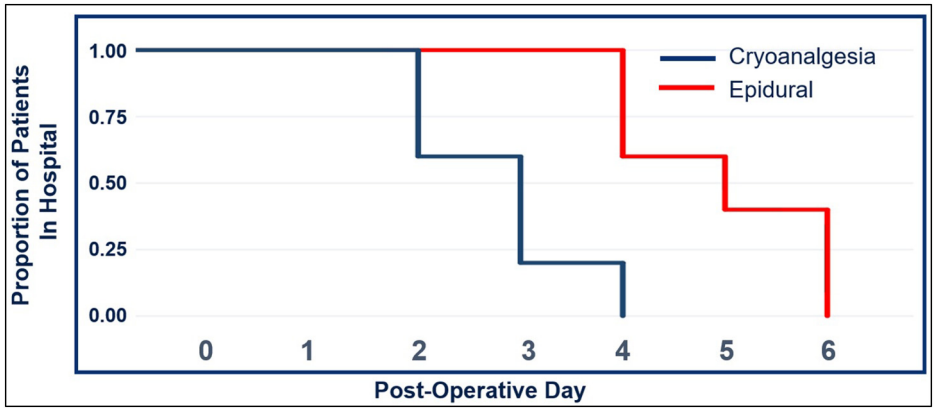

Fig. 2. Postoperative length of stay Median length of stay significantly decreased following cryoablation by Mann–Whitney U Test, $p = 0.0001$.

analgesia delivery are effective components of pain control regimens, they have limited durations of efficacy owing to both the half-life of the analgesic and the infection risk associated with prolonged use of an indwelling thoracic epidural catheter [33]. Additionally, some centers avoid the use of epidural catheters in favor of IV opioid administration, owing to high rates of failed catheter insertion, increased hospital costs and longer operating room times [11]. Although the risk of catastrophic neurologic injury associated with thoracic epidural is extremely small, some centers have abandoned their use altogether for this reason [11,34]. Despite these shortcomings, thoracic epidural catheters are effective and still widely used following the Nuss procedure. As thoracic epidural catheters were the standard practice at our institution, it was the most relevant practice to compare against cryoablation.

Cryoablation provides long-acting regional nerve blockade that outlasts injections and catheter-based delivery systems, providing analgesia throughout the postoperative period associated with the most severe pain. After cryoablation, sensation returns as the nerve axons regenerate within the intact nerve sheath. Importantly, all patients in our series regained normal sensation within 2–12 months after cryoablation. Furthermore, patients did not experience increased incidence of neuropathic symptoms or neuroma as the nerves recovered. We believe that complete nerve ablation by careful application of the cryoprobe, to less than −40 °C for 2 min is crucial to avoiding these complications.

The Nuss procedure is particularly well-suited to the use of cryoanalgesia because the intercostal nerves are clearly visualized thoracoscopically. The cryoablation technique used in this study used a double-lumen endotracheal tube (ETT) to allow for selective lung isolation to improve visualization of the nerves. Since completing the study, we have altered the operative technique to allow completion of the procedure with a single-lumen ETT. To accomplish this, cryoablation is performed prior to Nuss bar insertion, utilizing carbon dioxide insufflation to collapse the lung which affords excellent exposure of the nerves along the posterolateral chest wall. If this is attempted after Nuss bar placement, gas insufflation escapes around the bar insertion sites and exposure of the nerves is poor. An added advantage of pre-Nuss ablation is that it provides preventive analgesia, eliminating sensation prior to the most painful stimulus. Eliminating intubation with a double-lumen endotracheal tube also likely reduces costs and shortens operative times. Of note, great care should be taken to avoid touching the lung with the cryoprobe while cold, as damage to the lung parenchyma can result in delayed pneumothorax several days later. Though we found the provided protective sheath adequate, Morikawa et al. describe a method for additional insulation by using a chest tube to surround the probe [32].

While decreasing LOS and opioid use, application of cryoanalgesia increased operating room and operative times. The resulting increase in operating room-associated costs is likely completely offset by the two day decrease in hospital length of stay. Application of cryoanalgesia necessarily increases operative time by a minimum of 20 min, as a total of 10 nerves are ablated for 2 min each. The 69-min increase in operative time in the cryoablation group presents an opportunity to further streamline the technical aspects of cryoablation. However, the increased operative time in the cryoablation group resulted in a less pronounced increase in overall operating room time of 46.5 min. Eliminating the use of double lumen endotracheal tubes and more efficient application of cryoablation would likely result in operating room times on par with the epidural group.

This study was designed to more systematically evaluate the use of cryoanalgesia in the Nuss procedure and to validate results of previous retrospective studies. We attempted to control for selection bias with double-blinded randomization and only revealed the study arm just before surgery to limit any differences in preoperative preparation, either by patients and families or by hospital staff. Unfortunately, blinding to

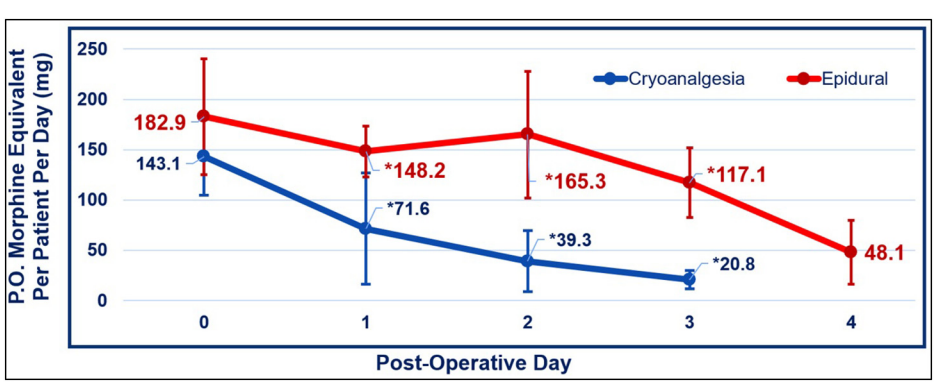

Fig. 3. Postoperative opioid requirement *indicates statistical significance, $p < 0.01$.

Please cite this article as: C.E. Graves, J. Moyer, M.J. Zobel, et al., Intraoperative intercostal nerve cryoablation during the Nuss procedure reduces length of stay and opioid requ..., Journal of Pediatric Surgery, https://doi.org/10.1016/j.jpedsurg.2019.02.057

ARTICLE IN PRESS

Table 2
Operative characteristics and postoperative pain characteristics.

	Thoracic epidural	Cryoablation	p-value
Room Time (min)			
Mean (Range)	156.0 (115–198)	202.5 (185–225)	***0.0001***
Operative Time (min)			
Mean (Range)	76.8 (63–111)	145.3 (128–167)	<***0.0001***
Mean Overall Pain Score[a]			
Day 1	3.0	3.1	0.88
Day 3	2.9	2.8	0.78
Day 5	2.8	--	--
2 Weeks	2.1	2.2	0.91
1 Month	1.9	2.5	0.58
3 Months	1.1	1.3	0.34
1 Year	1.1	1.3	0.34
Mean Neuropathic Pain Score[a]			
2 Weeks	1.9	3.0	0.32
1 Month	1.3	1.7	0.37
3 Months	2.1	1.9	0.80
1 Year	1.9	2.4	0.62
Anterior Chest Numbness (%)			
2 Weeks	20	100	
1 Month	20	100	
3 Months	0	60	
1 Year	0	0	

[a] Patients asked to rate overall and neuropathic pain on scale of 1 to 10, where 10 is maximum.

the intervention was not feasible in this study either for the surgeon or for the patient who awoke with or without an epidural catheter. Additionally, we felt that to ensure patient safety and to optimize individualized analgesia regimens, it was critical that the healthcare team be aware of which treatment patients received.

The biggest limitation of this study was the small sample size. Though we were able to demonstrate significant differences in LOS and opioid requirement between the two groups, the groups were not exactly matched as evidenced by a statistically significant difference in age between the groups. Of note, older patients are generally thought to have more rigid chest walls, which intuitively might contribute to greater postoperative pain and longer length of stays; yet the cryoanalgesia group, with a mean older age, experienced neither, suggesting differences in age did not affect our results. Though the numbers in this study are too small for subgroup analysis, as we expand our cohort, we hope to further define patient factors such as age, habitus, and Haller index that may predict increased benefit from cryoanalgesia.

In summary, the results of this prospective, randomized trial demonstrate that intraoperative intercostal nerve cryoablation shortens LOS and reduces inpatient opioid use after the Nuss procedure when compared to thoracic epidural, while providing equivalent pain control. This improved analgesia does not appear to be associated with increased risk of complications, such as neuropathic pain or permanent loss of sensation.

Funding

This work was funded by the National Institutes of Health, NIH Grant 5R03HD090617-02.

Clinical trial registration information

ClinicalTrials.gov; ID: NCT02721017. "Pain Control in the Nuss Procedure: A Prospective, Randomized Trial of Cryoanalgesia vs. Thoracic Epidural" https://clinicaltrials.gov/ct2/show/NCT02721017

Institutional review board information

UCSF Human Research Protection Program/ Institutional Review Board #15-18202.

Appendix A. Pectus excavatum postop pain control

POD #0	#1	#2	#3	#4	#5	#6	
X	X	X	X				**Epidural, 0.1% ropivacaine, 2 μg/cc fentanyl, 6 cc/h, Pain Service** Wean POD 2–3 (may vary based on individual patient)
X	X	X					**Acetaminophen IV (Ofirmev)15 mg/kg, Pain Service** (once taking POs can be switched to oral Tylenol — should be taking orals by POD#2)
X	X	X					**Toradol IV × 48 h, Pain Service** (switch to Ibuprofen POD 2)
X	X	X	X	X			**Dilaudid PCA, 0.1 mg q10min prn, Pain Service** (wean as able, likely POD 1–2)
X	X	X	X	X	X	X	***Oxycodone 5 mg PO Q 6 h ATC plus Q 3 h PRN** (should start once taking good POs)
	X	X	X	X	X	X	***Oxycontin 10 mg BID — ONLY IF NEEDED**
	X	X	X	X	X	X	***Acetaminophen 650 mg po q6h ATC**
		X	X	X	X	X	***Ibuprofen 10 mg/kg/dose Q 6 h ATC** Max dose: 600–800 mg Q 6 h ATC
X	X	X	X	X	X	X	***Zofran — 4 mg IV then PO Q 6 h PRN** (for severe nausea can increase dose to 8 mg Q 8 h PO/ IV) *continue on discharge only if needed
	X	X	X	X	X	X	***Miralax — 17 g TID**
	X	X	X	X	X	X	***Senna — 1-2 tables Q HS**
		X	X	X	X	X	***PPI or H2 Blocker** Suggested: Ranitidine 150 mg PO QD
			X	X	X	X	***Baclofen** — skeletal muscle relaxant

All patients should receive the above medications (with exception of epidural) regardless of study arm. These are general guidelines and will vary by individual patient. Each case should be discussed by Pedi Surgery and IP3 preoperatively for intraop plan of care, and again postop.

* **Starred medications should be continued on discharge.**

Obtain PA and lateral CXR prior to D/C.
Revised for Nuss trial, 12/2015.

References

[1] de Oliveira Carvalho PE, da Silva MV, Rodrigues OR, et al. Surgical interventions for treating pectus excavatum. Cochrane Database Syst Rev 2014:Cd008889.
[2] Nuss D, Kelly Jr RE, Croitoru DP, et al. A 10-year review of a minimally invasive technique for the correction of pectus excavatum. J Pediatr Surg 1998;33:545–52.
[3] Mao YZ, Tang S, Li S. Comparison of the nuss versus ravitch procedure for pectus excavatum repair: an updated meta-analysis. J Pediatr Surg 2017;52:1545–52.
[4] Kelly RE, Goretsky MJ, Obermeyer R, et al. Twenty-one years of experience with minimally invasive repair of pectus excavatum by the Nuss procedure in 1215 patients. Ann Surg 2010;252:1072–81.
[5] Kelly Jr RE, Mellins RB, Shamberger RC, et al. Multicenter study of pectus excavatum, final report: complications, static/exercise pulmonary function, and anatomic outcomes. J Am Coll Surg 2013;217:1080–9.
[6] Kelly Jr RE, Shamberger RC, Mellins RB, et al. Prospective multicenter study of surgical correction of pectus excavatum: design, perioperative complications, pain, and baseline pulmonary function facilitated by internet-based data collection. J Am Coll Surg 2007;205:205–16.
[7] Densmore JC, Peterson DB, Stahovic LL, et al. Initial surgical and pain management outcomes after nuss procedure. J Pediatr Surg 2010;45:1767–71.
[8] Ghionzoli M, Brandigi E, Messineo A, et al. Pain and anxiety management in minimally invasive repair of pectus excavatum. Korean J Pain 2012;25:267–71.
[9] Papic JC, Finnell SM, Howenstein AM, et al. Postoperative opioid analgesic use after Nuss versus Ravitch pectus excavatum repair. J Pediatr Surg 2014;49:919–23 [discussion 23].
[10] Stroud AM, Tulanont DD, Coates TE, et al. Epidural analgesia versus intravenous patient-controlled analgesia following minimally invasive pectus excavatum repair: a systematic review and meta-analysis. J Pediatr Surg 2014;49:798–806.
[11] St Peter SD, Weesner KA, Weissend EE, et al. Epidural vs patient-controlled analgesia for postoperative pain after pectus excavatum repair: a prospective, randomized trial. J Pediatr Surg 2012;47:148–53.
[12] Weber T, Matzl J, Rokitansky A, et al. Superior postoperative pain relief with thoracic epidural analgesia versus intravenous patient-controlled analgesia after minimally invasive pectus excavatum repair. J Thorac Cardiovasc Surg 2007;134:865–70.

Please cite this article as: C.E. Graves, J. Moyer, M.J. Zobel, et al., Intraoperative intercostal nerve cryoablation during the Nuss procedure reduces length of stay and opioid requ..., Journal of Pediatric Surgery, https://doi.org/10.1016/j.jpedsurg.2019.02.057

ARTICLE IN PRESS

[13] Hall Burton DM, Boretsky KR. A comparison of paravertebral nerve block catheters and thoracic epidural catheters for postoperative analgesia following the Nuss procedure for pectus excavatum repair. Paediatr Anaesth 2014;24:516–20.
[14] Lukosiene L, Macas A, Trepenaitis D, et al. Single shot intercostal block for pain management in pediatric patients undergoing the nuss procedure: a double-blind, randomized, controlled study. J Pediatr Surg 2014;49:1753–7.
[15] Choudhry DK, Brenn BR, Sacks K, et al. Continuous chest wall ropivacaine infusion for analgesia in children undergoing nuss procedure: a comparison with thoracic epidural. Paediatr Anaesth 2016;26:582–9.
[16] Loftus PD, Elder CT, Russell KW, et al. Paravertebral regional blocks decrease length of stay following surgery for pectus excavatum in children. J Pediatr Surg 2016;51:149–53.
[17] Beltran R, Veneziano G, Bhalla T, et al. Postoperative pain management in patients undergoing thoracoscopic repair of pectus excavatum: a retrospective analysis of opioid consumption and adverse effects in adolescents. Saudi J Anaesth 2017;11:427–31.
[18] Bryskin RB, Robie DK, Mansfield FM, et al. Introduction of a novel ultrasound-guided extrathoracic sub-paraspinal block for control of perioperative pain in nuss procedure patients. J Pediatr Surg 2017;52:484–91.
[19] Kabagambe SK, Goodman LF, Chen YJ, et al. Subcutaneous local anesthetic infusion could eliminate use of epidural analgesia after the nuss procedure. Pain Manag 2018;8:9–13.
[20] Nuss D, Obermeyer RJ, Kelly RE. Nuss bar procedure: past, present and future. Ann Cardiothorac Surg 2016;5:422–33.
[21] Kim S, Idowu O, Palmer B, et al. Use of transthoracic cryoanalgesia during the nuss procedure. J Thorac Cardiovasc Surg 2016;151:887–8.
[22] Graves C, Idowu O, Lee S, et al. Intraoperative cryoanalgesia for managing pain after the nuss procedure. J Pediatr Surg 2017;52(6):920–4.
[23] Sujka J, Benedict LA, Fraser JD, et al. Outcomes using cryoablation for postoperative pain control in children following minimally invasive pectus excavatum repair. J Laparoendosc Adv Surg Tech A 2018 Nov;28(11):1383–6.
[24] Lloyd JW, Barnard JDW, Glynn CJ. Cryoanalgesia: a new approach to pain relief. Lancet 1976;308:932–4.
[25] Evans PJ. Cryoanalgesia. The application of low temperatures to nerves to produce anaesthesia or analgesia. Anaesthesia 1981;36:1003–13.
[26] Hippocrates. Aphorisms, v. Xxm. Xxv: Hippocrates vol iv heracleitus on the universe. London: William Heinemann Ltd.; 1931.
[27] Moorjani N, Zhao F, Tian Y, et al. Effects of cryoanalgesia on p-thoracotomy pain and on the structure of intercostal nerves: a human prospective randomized trial and a histological study. Eur J Cardiothorac Surg 2001;20:502–7.
[28] Evans PJ, Lloyd JW, Green CJ. Cryoanalgesia: the response to alterations in freeze cycle and temperature. Br J Anaesth 1981;53:1121–7.
[29] Denny-Brown D, Adams RD, et al. The pathology of injury to nerve induced by cold. J Neuropathol Exp Neurol 1945;4:305–23.
[30] Beazley RM, Bagley DH, Ketcham AS. The effect of cryosurgery on peripheral nerves. J Surg Res 1974;16:231–4.
[31] Keller BA, Kabagambe SK, Becker JC, et al. Intercostal nerve cryoablation versus thoracic epidural catheters for postoperative analgesia following pectus excavatum repair: preliminary outcomes in twenty-six cryoablation patients. J Pediatr Surg 2016;51:2033–8.
[32] Morikawa N, Laferriere N, Koo S, et al. Cryoanalgesia in patients undergoing nuss repair of pectus excavatum: technique modification and early results. J Laparoendosc Adv Surg Tech A 2018;28(9):1148–51.
[33] BombergH Bayer I, Wagenpfeil S, et al. Prolonged catheter use and infection in regional anesthesia: a retrospective registry analysis. Anesthesiology 2018;128:764–73.
[34] Polaner D, et al. Pediatric regional anesthesia network: a multi-institutional study of the use and incidence of complications of pediatric regional anesthesia. Anesth Analg 2012;115:1353–64.

Please cite this article as: C.E. Graves, J. Moyer, M.J. Zobel, et al., Intraoperative intercostal nerve cryoablation during the Nuss procedure reduces length of stay and opioid requ..., Journal of Pediatric Surgery, https://doi.org/10.1016/j.jpedsurg.2019.02.057